

Rotator cuff problems in sport

TOM CROSS MB BS, FACSP, DCH

Series Editor **KEN CRICHTON** MB BS(Hons), FACSP

The rotator cuff is critical for normal shoulder kinematics. It is important to accurately diagnose and treat these injuries to ensure an expeditious return to best possible function and, moreover, minimise the risk of progressive injury to the shoulder.

Shoulder problems are common in sports medicine practice. Subacromial bursitis and rotator cuff tendinopathy (ranging from low grade tendinosis to partial or full thickness tears) have long been implicated as causes of pain, weakness and functional limitation about the shoulder. This article presents an approach to the more common shoulder presentations in which the rotator cuff is injured.

Anatomy

The tendinous insertions of the four rotator cuff muscles of the shoulder (supraspinatus, infraspinatus, teres minor and

subscapularis) and the lateral part of the articular capsule blend into a confluent sheet of tissue before insertion into the humeral tuberosities (Figures 1a and b). This fused mass of tendons and lateral part of the capsule is known as the rotator cuff, which plays two dynamic roles in shoulder function:

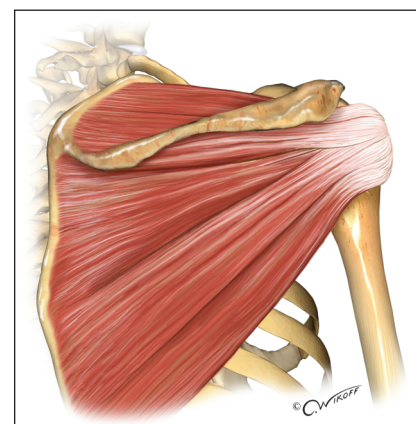
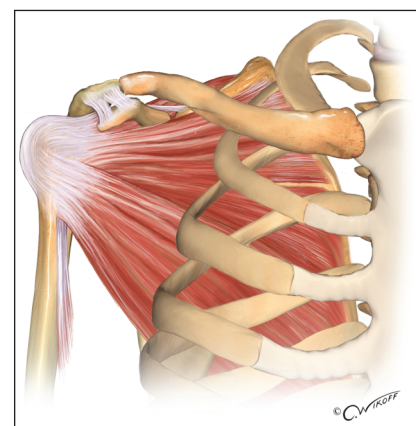
- stabilisation of the humeral head in the glenoid
- rotation of the humerus.

The rotator cuff is very important for activities of daily living and also for many sporting pursuits. Both recreational and elite sportspeople (particularly those who are involved in overhead/throwing sports and collision sports) can make considerable functional demands of the cuff that may result in injury.

Pathophysiology

The pathophysiology of rotator cuff disease or injury is complex and considered to be the end result of multiple contributing factors. Intrinsic factors include age related degenerative changes in the tendons. Extrinsic factors include:

- constitutional or degenerative outlet obstruction (subacromial impingement) – for example, a curved or hooked acromion, subacromial osteophytes, acromioclavicular joint osteophytes



Figures 1a and b. Anatomy of the rotator cuff in anterior (a, top) and posterior (b, above) views.

- a single acute traumatic event (macro-trauma)
- repetitive overuse (micro-trauma)
- shoulder instability or laxity (usually anterior).

In a sportsperson, one or more of the above may result in rotator cuff injury, a continuum of pathologies ranging from low grade subacromial bursitis and rotator cuff tendinosis to massive (>5 cm in length) rotator cuff tendon tears. Partial thickness tears exist within this continuum, and are increasingly being recognised in sportspeople and in the general population.

The age of the patient is important to consider. Athletes under 40 years of age usually injure their rotator cuff secondary

Dr Cross is a Sports Physician, North Sydney Sports Medicine Centre, Crows Nest, and Sydney Sports Med Clinic, Circular Quay. He has practised sports medicine for 10 years and is presently one of the team physicians for the NSW Waratahs rugby union club. Series Editor: Dr Crichton is Director of Sports Medicine at North Sydney Orthopaedic and Sports Medicine Centre, and a Consultant Sports Physician at the Children's Hospital Institute of Sports Medicine, Westmead, Sydney, NSW.



© CHRIS WIKOFF, 2006

Diagnosing and managing rotator cuff injuries – clinical examples

Case 1

Presentation: A 14-year-old swimmer presents with gradual onset of left lateral shoulder pain. She swims nine squad sessions per week and is preparing for the State titles.

Commentary: This patient has rotator cuff tendinopathy and/or subacromial bursitis until proven otherwise. An important differential diagnosis is a symptomatic os acromiale (accessory ossicle of acromium). Contributing glenohumeral laxity or instability should be suspected in any athlete participating in an overhead sport, particularly swimming or a throwing sport.

Pertinent features to look for in this patient's history include:

- a training history – has there been a 'training error', with an excessively rapid progression of volume, intensity or frequency of swimming?
- preferred strokes (freestyle and butterfly are the most demanding on the rotator cuff)
- past shoulder or overuse injury
- a recent change in coach, which may be associated with a training error or a change in swimming technique
- swimming biomechanics and any identified technique flaws (e.g. breathing only to one side, insufficient body roll, 'dropping the elbow' in the catch phase of the stroke).

A thorough shoulder examination is indicated, with the patient undressed to a bra. Excessive kyphosis or scoliosis causing shoulder protraction should be sought, and the range of spinal motion (particularly thoracic rotation) assessed. The lateral acromion should be palpated for a symptomatic os acromiale and the shoulders assessed for laxity (sulcus sign, translation and excessive range of motion) and instability (apprehension/relocation test). Impingement tests and rotator cuff strength tests are essential.²

Imaging is not usually indicated in this scenario, unless the problem is recurrent or there is tenderness of the lateral acromion. In such cases, an x-ray series of the shoulder (with or without an ultrasound) should be performed to assess for acromial morphology (os acromiale, curved or hooked acromion), rotator cuff tendinopathy, subacromial bursitis and impingement.

Treatment involves simple analgesia and a short course of low dose oral anti-inflammatory agents. The severity of symptoms will guide activity modification (a period of no swimming, kickboard use only, decreased volume of swimming). Physiotherapy is indicated, with anti-inflammatory modalities, soft tissue therapy (including identifying and correcting excessive capsular tightness, particularly the posterior capsule) and scapular re-training. These strategies should then be followed by a graduated rotator cuff strengthening program and with attention paid to spinal stability and range of motion. Subacromial cortisone is rarely used or necessary in

paediatric patients. Rarely, referral to a specialist orthopaedic shoulder surgeon may be indicated.

When she is asymptomatic, this patient should make a gradual return to her usual training. At that stage, any technique flaws in her stroke(s) should be identified and corrected to prevent a recurrence. Rehabilitation may be prolonged and she may be prone to recurrence, particularly if associated shoulder joint laxity or instability is present.

Case 2

Presentation: A 21-year-old rugby union forward tackles a 110 kg opponent and dislocates his left shoulder. The shoulder is reduced at the local hospital two hours later. He undergoes physiotherapy, but presents six weeks later with ongoing pain and weakness.

Commentary: This patient has a rotator cuff tear until proven otherwise. This is a rare but important concomitant injury associated with traumatic instability of the shoulder in patients under 40 years of age.^{4,5} The physician should also be vigilant for the complication of a neurological injury (e.g. axillary nerve palsy).

Pertinent features to look for in the history include previous left shoulder injury (tendinopathy, instability and surgery) and anabolic steroid use (which increases the risk of tendinosis injury). Examination should include rotator cuff strength tests, impingement tests, laxity and

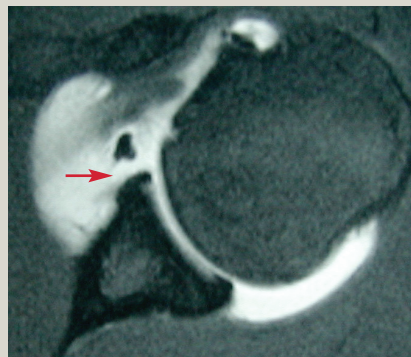


Figure 2a. MRI axial view of a soft tissue Bankart lesion.

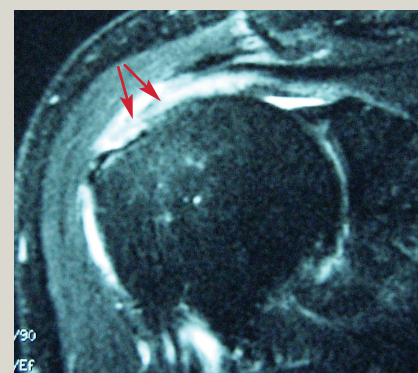


Figure 2b. MRI coronal view of a full thickness tear of the supraspinatus tendon.

instability tests and labral tests. A neurovascular assessment should be performed.

Ideally, investigation would include an instability x-ray series and MRI to assess the capsulo-labral-ligamentous structures and the rotator cuff; ultrasound assessment of the cuff would be adequate if MRI is not available or the cost is prohibitive.

In this case, x-ray demonstrated a Hill-Sachs' lesion⁶ and MRI demonstrated a soft tissue Bankart lesion⁶ and a full thickness supraspinatus tendon tear (Figures 2a and b). The patient was referred to a specialist orthopaedic shoulder surgeon and underwent a two-stage repair (initial repair of the rotator cuff and left shoulder reconstruction 10 weeks thereafter).⁴

Case 3

Presentation: A 48-year-old male left handed tennis player presents with a two-month history of gradual onset of left lateral shoulder pain and weakness, particularly noted when serving in tennis.

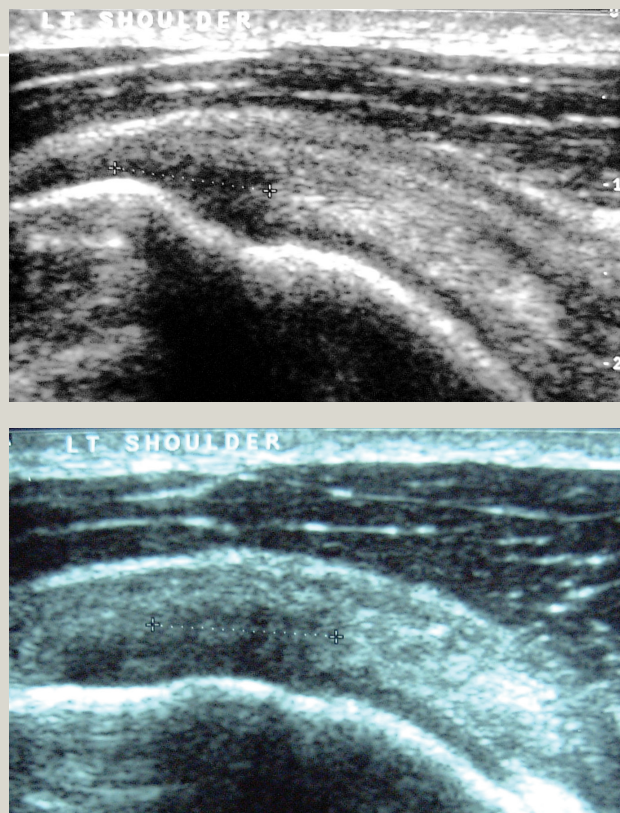
Commentary: This patient has an injury to his left shoulder rotator cuff until proven otherwise. The possibilities range from subacromial bursitis and/or tendinosis to a partial or full thickness tear. Associated laxity or instability of the shoulder is an important consideration.

Pertinent features to look for in the history include previous shoulder injury (tendinopathy, instability and surgery) and symptoms that may suggest an instability event ('dead arm' symptoms). The patient should be questioned about 'training errors' and technique and/or equipment changes (e.g. new racquet, focus on kick serve). Examination should include rotator cuff strength tests, impingement tests, laxity and instability tests and labral tests. A neurovascular assessment should be performed.²

In this case, the clinical evaluation is suggestive of rotator cuff pathology. An impingement x-ray series and ultrasound were performed, which demonstrated an articular sided partial thickness tear of the supraspinatus tendon (Figures 3a and b), mild subacromial bursitis and dynamic impingement.

No simple treatment algorithm for partial-thickness rotator cuff tears exists.⁸ Treatment for this patient should involve an initial trial of nonsurgical management, with avoidance of aggravating activities (tennis and other overhead sports) for a variable period (six weeks to six months), analgesics (if necessary) and a short course of oral anti-inflammatory medication. Consideration should be given to a subacromial corticosteroid injection (either initially or, if rehabilitation is slow, in four to six weeks).

A dedicated physiotherapy program is essential, with anti-inflammatory modalities, stretching of tight capsular structures, particularly the posterior capsule, and re-establishment of normal shoulder kinematics. Scapular control and retraction exercises need



Figures 3a and b. Ultrasound demonstrating an articular side partial thickness tear of the supraspinatus tendon, in longitudinal (a, top) and transverse (b, above) views.

to be emphasised initially. As pain decreases and shoulder function improves, attention is focused on strengthening the rotator cuff – initially with the elbow by the side and then, with progression, with the shoulder abducted to 90° (through a functional range of motion). Thereafter, eccentric and pylometric strengthening of the cuff is performed, and the patient can make a gradual return to tennis. Importantly, any potentially causal factors (e.g. technique errors, racquet too tightly strung) should be addressed to prevent a recurrence.

The indications for surgery have not been firmly established in patients with symptomatic partial thickness rotator cuff tears, but failure to improve after three to six months of nonoperative treatment has been recommended as an indication. Surgical management involves one of three options: arthroscopic debridement of the tear, debridement with acromioplasty, or rotator cuff repair with or without acromioplasty.⁸ In patients who are treated nonsurgically (or surgically without repair of the tear), 'tear progression' is an important consideration. Studies suggest that patients with partial thickness rotator cuff tears require careful follow up, with tear progression occurring in up to 80% of such cases after two years.⁹

Diagnosing and managing rotator cuff injuries continued

Case 4

Presentation: A 54-year-old professional horse trainer falls off her horse, landing on an outstretched right arm. She describes pain and a tearing sensation in her right shoulder at the time of injury. She undergoes three weeks of physiotherapy, but presents with ongoing pain and weakness.

Commentary: This patient has a rotator cuff tear until proven otherwise. An associated bony, joint or neurovascular injury should also be considered.

Pertinent features to look for in the history include previous shoulder injury (tendinopathy, instability and surgery), handedness, and symptoms that may suggest an instability event ('dead arm' symptoms) or fracture (significant pain, loss of function). Examination should be directed in particular to rotator cuff strength tests (Figure 4a), impingement tests, laxity and instability tests and labral tests. A neurovascular assessment should be performed.

Ideally, investigations should include an instability x-ray series and MRI to assess the capsulo-labral-ligamentous structures and the rotator cuff. Ultrasound would be adequate if MRI is not available.

In general, indications for surgery for full thickness rotator cuff tears involve consideration of patient factors, such as age, handedness and demands on the affected shoulder (occupational, sporting and recreational). Tear characteristics also need to be considered (acute versus chronic, size, degree of retraction, association with significant degenerative changes of the remaining rotator cuff and fatty atrophy of the affected muscles).¹⁰

In this case, an x-ray and MRI demonstrated a moderate sized full thickness tear of the supraspinatus tendon (Figure 4b). That this patient was right handed, was involved in a high demand occupation and sport, had significant dysfunction associated with a moderate sized acute supraspinatus tendon tear and that the remainder of the rotator cuff was not degenerative on MRI were important considerations. She was referred to an orthopaedic surgeon and promptly underwent a rotator cuff repair. Rehabilitation after a rotator cuff repair is slow (six to 12 months) and patients need to be aware of this. She subsequently made an excellent recovery and returned to full activity.

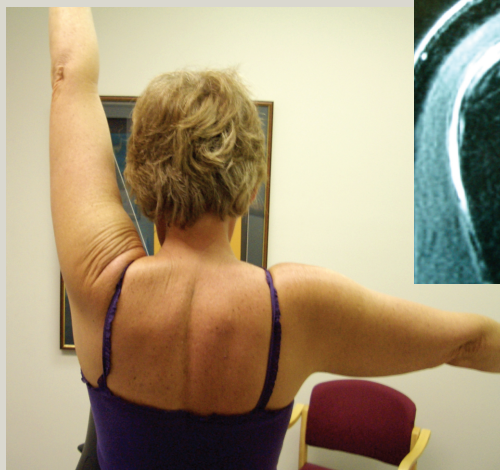

Figure 4a. Weakness of abduction of the right shoulder.

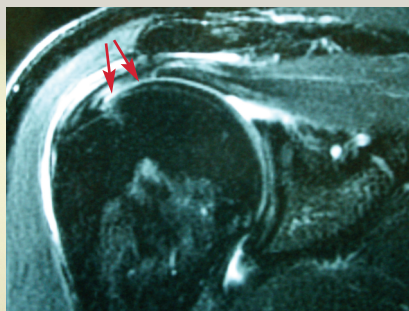


Figure 4b. MRI of full thickness supraspinatus tendon tear.

to significant repetitive micro-trauma (e.g. throwing, swimming) or high energy macro-trauma (e.g. falling on an outstretched arm, tackling an opponent). Athletes over 40 years of age are more susceptible to degenerate lesions or tears in the cuff and/or outlet obstruction, and therefore have a lower threshold for both micro- and macro-traumatic injury.

Certain sports are more commonly associated with rotator cuff problems. Overhead sports (e.g. swimming, water polo, racquet sports, baseball, javelin) are associated with micro-traumatic injury, whereas collision sports (e.g. some football codes) and sports associated with falls (e.g. skiing, mountain biking) may cause macro-traumatic injury.

In younger athletes, in particular, the physician should always suspect concomitant shoulder laxity or instability that may coexist with the rotator cuff problem and exacerbate it. Glenohumeral laxity secondary to gradual attenuation of the capsule-ligamentous structures can develop in an athlete who participates in a throwing sport and can predispose to rotator cuff micro-trauma, whereas frank glenohumeral instability events (subluxation/dislocation) may cause macro-traumatic injury. In general terms, high energy instability events are usually required to injure the cuff in younger patients, whereas lower energy instability events can be responsible for injury in older patients.

Evaluation

A thorough description of history taking and examination techniques for rotator cuff injury is beyond the scope of this article, and readers are referred to several excellent references.¹⁻³ The four case scenarios on pages 76, 77 and this page illustrate an approach to common rotator cuff problems in sports medicine.

Investigation

It should be appreciated that routine anterior-posterior and lateral x-ray views

of the shoulder are often inadequate to fully assess the shoulder for a suspected rotator cuff injury. Either an impingement series (anterior–posterior with internal and external rotation, lateral, axial, outlet, anterior–posterior with 30° tube down-tilt) or instability series is recommended. This should preferably be performed at a radiology practice with an interest in musculoskeletal imaging.⁶

Ultrasound gives a static and dynamic assessment of the cuff, and can be both diagnostic and therapeutic when a guided subacromial cortisone injection is given, but it is highly operator dependent. MRI yields the greatest diagnostic information affording assessment of bony, joint, ligamentous and musculotendinous structures.⁶

Treatment

Subacromial cortisone injections may be given for a range of rotator cuff pathologies (tendinopathy, bursitis, partial and full thickness tears). There are no published guidelines on when or how often to perform this procedure. It is important to be aware of the potential catabolic effect of cortisone on the cuff and other potential side effects and complications.⁷ As a rule, most physicians do not recommend more than three injections of cortisone into any single site within 12 months, but this is an arbitrary time period.

It is recommended that an x-ray be obtained before performing an office subacromial cortisone injection. This enables appreciation of the acromial morphology and avoids injection in the presence of avascular necrosis of the humeral head, which may rarely mimic rotator cuff pathology.

Final comments

The rotator cuff is a finely tuned musculoskeletal structure that is critical for normal shoulder kinematics. It is, however, prone to a spectrum of injury when its 'envelope of function' is exceeded. It is incumbent on the physician not only to

diagnose the degree of injury to the cuff but also to establish the intrinsic or extrinsic forces responsible so that the risk of ongoing or recurrent injury can be minimised. Treatment is directed to returning the patient to the comfort and function of being within the 'envelope'. This will usually involve a nonsurgical approach, but on occasion surgical procedures are indicated. **MT**

References

1. Tennent TD, Beach WR, Meyers JF. A review of the special tests associated with shoulder examination. Part 1: the rotator cuff tests. *Am J Sports Med* 2003; 31: 154-160.
2. Brukner P, Khan K. *Clinical sports medicine*, 3rd ed. Sydney: McGraw-Hill; 2006.
3. Watson EM, Sonnabend DH. *Shoulder problems: a guide to common disorders*. *Med Today* 2000; 1(1): 22-30.
4. Goldberg JA, Chan KY, Best JP, Bruce WJ, Walsh W, Parry W. Surgical management of large rotator cuff tears combined with instability in elite rugby football players. *Br J Sports Med* 2003; 37: 179-181.
5. Tarkin IS, Morganti CM, Zillmer DA, McFarland EG, Giangarra CE. Rotator cuff tears in adolescent athletes. *Am J Sports Med* 2005; 33: 596-601.
6. Anderson J, Read JW, Steinweg J. *Atlas of imaging in sports medicine*. Sydney: McGraw-Hill; 1999.
7. Nichols AW. Complications associated with the use of corticosteroids in the treatment of athletic injuries. *Clin J Sport Med* 2005; 15: 370-375.
8. Matava MJ, Purcell DB, Rudzki JR. Partial-thickness rotator cuff tears. *Am J Sports Med* 2005; 33: 1405-1417.
9. Yamanaka K, Matsumoto T. The joint side tear of the rotator cuff. A followup study by arthrography. *Clin Orthop Relat Res* 1994; 304: 68-73.
10. Garrett W, Speer K, Kirkendall DT. *Principles and practice of orthopaedic sports medicine*. Philadelphia: Lippincott Williams & Wilkins; 2000.

DECLARATION OF INTEREST: None.